



Therapeutic effect of methanolic leaves extract of cannabis in copper induced cardio-toxicity in wistar rats

I M Hassan*, B Sa'idu, A Dahiru, Abdulazeez, B Aliyu, B Y Aliyu

Department of Veterinary Physiology and Biochemistry, Usmanu Danfodiyo University Sokoto, Sokoto, Nigeria

Abstract

The aim of this investigation was to study the effect of cannabis on hematological parameters of wistar rats induced with copper toxicity. Twenty (20) rats were randomly divided into four groups of five rats each. Group A (negative control) received water only for 15 days, Group B received copper at 200 mg/kg for five days, Group C received copper at 200 mg/kg for five days then treated with cannabis at 300 mg/kg for ten days and Group D received cannabis at 300mg/kg only for ten days. All the rats were sacrificed on day sixteen and blood was collected through cardiac puncture and analyzed. Prepared slides from the heart were dehydrated using a dry air oven in xylene for 30 minutes and later mounted on the microscope and viewed using oil immersion $\times 1000$ magnification. In group induced with copper we observed decrease in PVC, RBC and WBC. Leucopenia, lymphopenia, monocytopenia and eosinopenia were also observed. However, there was increase in MCHC, MCH and MCV. The result of this study shows that copper caused changes on hematological parameters that lead to anemia, also treatment with cannabis caused relative increase in hematological parameters which was not significant enough to reverse the effect. However, cannabis only was able to caused polycythemia.

Keywords: cannabis, copper ii oxide, heart, hematology and histopathological

Introduction

Copper is an important micronutrient for all living things. Copper is a cofactor in many enzyme activities, despite its ability to quickly absorb and lose an electron. Some reduce oxidative stress and are an important component of electron transport in the mitochondrial respiratory chain and chloroplasts, where they are integrated into plastocyanin (Rehman *et al.*, 2019). Copper, on the other hand, is a heavy metal, and the redox feature that makes it so important also adds to its intrinsic toxicity at large quantities (Fashola, Ngole-Jeme, & Babalola, 2016) ^[6]. Through sHaber–Weiss and Fenton reactions, it can produce reactive oxygen species (ROS) such as superoxide and hydroxyl radicals, which can damage cellular components (proteins, amino acids, nucleic acids, membrane lipids), interfere with cellular transport processes, and cause changes in essential metabolite concentrations (Yalcinkaya, Uzilday, Ozgur, Turkan, & Mano, 2019) ^[18]. Because both copper shortage and toxicity may cause cellular harm, cells develop a tight control of the free copper level, mostly through producing extremely effective metal-chelating proteins (Park, Oh, Wagner, Panganiban, & Lu, 2017) ^[12]. The United Nations Single Convention on Narcotic Drugs of 1961 defines cannabis, popularly known as marijuana, as "the blossoming of the Cannabis plant's fruiting tops" (Cannabis) (Bewley-Taylor & Jelsma, 2012) ^[3]. The medicinal use of cannabis and its metabolites, phyto cannabinoids, notably delta-9-tetrahydrocannabinol (THC), continues to attract substantial clinical and public interest (Kocis & Vrana, 2020). Medicinal cannabis, on the other hand, is still a relatively new clinical pharmacology area, and our understanding of its human and animal toxicity profile is still in progress.

The pharmaceutical approach to the production of medicinal cannabis necessitates a comprehensive toxicity evaluation of the cannabis and standardized formulations to reduce undesirable effects. Unadulterated cannabis is typically seen as a relatively safe medicine with a manageable side effect profile by the nonmedical community (Hunt *et al.*, 2003) ^[8].

The incidence and consequences of harmful abiotic and biotic pollutants, on the other hand, remain mostly unknown. However, there are significant uncertainties surrounding the prevalence and effects of toxic abiotic and biotic contaminants (Bergamaschi, Helena, Queiroz, Crippa, & Zuardi, 2011). Despite its rising popularity as a supplement and/or medicinal agent, little is known regarding the cardio-therapeutic benefits of cannabis leaf and seed. As a result, the current study looked at the cardio-therapeutic effects of cannabis methanol leaf extract on Wistar rats.

Material and method

Cannabis leaves were obtained from Sokoto, Nigeria. The leaves were crushed into semi powdered form using mortar and pestle and then soaked into 80% methanol and kept at room temperature free of dust for seven days. It was sieved using soft cotton cloths and kept for seven days at room temperature for partial methanol evaporation followed by concentration with rotary evaporator at 42 °C and subsequently freeze dried. The yield of the freeze-dried sample representing the aqueous extract obtained.

Study design

After acclimatization period of 3 weeks, animals were divided randomly in to 4 groups of 5 rats each.

Group 1 serving as negative control receiving only feed and water for 15 days.

Group 2 serving as positive control receiving copper 200 mg/kg only for 15 days.

Group 3 received copper II oxide 200 mg/kg for 5 days and later treated with cannabis 300 mg/kg for 10 days and

Group 4 were given cannabis only 300 mg/kg for 15 days.

Haematology

The PCV, RBC, Hgb, MCV, total white blood cell counts and differential white blood cell counts were all determined immediately from the blood samples. Standard protocols were followed for all haematological tests. PCV was evaluated using the microhaematocrit method (Onyemaobi and Onimawo, 2011) [11], and Hgb was assessed using the cyanomethaemoglobin method (Higgins, 2008) [7]. The haemocytometer method was used to count RBC and WBC utilizing Natt and Herrick's solution as the diluting fluid (Natt and Herrick, 1952). The Leishman technique was used to prepare and stain the smears for differential WBC as enumerated by the battlement counting method (Fasakin, 2014). Formulas were used to calculate the results of MCV, MCH, and MCH (Wheby, 1980).

Histological Study

The heart was soaked in fixative (10% neutral buffered formalin) for three days before being transferred straight to 70% alcohol, where it was graded to 90%, 99%, and 100% alcohol for eight, twelve, and fifteen hours, respectively. After replacing the alcohol with Xylene and incubating the tissues for 4 hours, they were embedded and inserted into paraffin wax to harden the tissue for easy cutting into thin pieces using the microtome. Tissues were cast into a paraffin block in a 'L' shape to eliminate air bubbles before solidification. The prepared slides were dried in xylene using a dry air oven for 30 minutes before being put on the microscope and observed under oil immersion at 1000 magnification (Sabdyusheva *et al.*, 2020).

Statistical Method

The data for this study was analyzed using *In vivo* statistical Software (version 4.2). Where statistical difference existed, Behrens Fisher tests were used to separate the mean.

Table 1: Effect of cannabis on copper induced hematological changes in wistar rats. (N=20)

Parameters	A	B	C	D
PCV%	39.5± 0.95 ^a	35.00± 0.40 ^b	37.75± 2.56 ^{ab}	40.75± 1.65 ^a
Hb(g/dl)	12.81± 0.26	12.55± 0.91	12.4± 0.86	13.39± 0.45
RBC(X10 ⁶ MM ³)	7.82± 1.18 ^b	5.95± 0.32 ^b	7.64± 0.77 ^a	11.00± 1.94 ^b
WBC (X10 ³ MM ³)	6.04± 0.76 ^{ab}	5.98± 0.48 ^a	4.72± 0.13 ^b	5.41± 0.37 ^{ab}
MCHC(g/dl)	33.95± 1.59 ^{ab}	35.85± 0.15 ^a	33.15± 1.31 ^{ab}	32.95± 0.50 ^b
MCH (pg.)	17.77± 2.58 ^{abc}	21.22± 0.79 ^a	16.47± 0.67 ^b	13.52± 2.56 ^{bc}
MCV (FL)	54.07± 8.21 ^{ab}	59.20± 2.45 ^a	49.5± 2.07 ^b	41.00± 7.77 ^{ab}
L%	67.00± 4.74	70.5± 0.64	70.75± 2.59	70.25± 4.25
N%	30.00± 4.35	27.75± 0.85	27.00± 2.73	28.00± 4.84
M%	2.75± 0.47 ^a	1.25± 0.25 ^b	2.25± 0.47 ^a	1.50± 0.64 ^a
E%	0.25± 0.25	0.50± 0.28	0.25± 0.25	0.25± 0.25
B%	0.00± 0.00	0.00± 0.00	0.00± 0.00	0.00± 0.00

Key: A (negative control), B (copper only), C (copper then cannabis), D (cannabis only), PCV (packed cell volume), Hb(hemoglobin), RBC(red blood cells), WBC(white blood cells), MCHC(mean corpuscular hemoglobin), MCH(mean corpuscular hemoglobin), MCV(mean corpuscular volume), L%(lymphocytes), N%(neutrophils), M%(monocytes), E%(eosinophils), B%(basophils). Data is given as means ± standard deviation. ^{abc} means in a row with different superscripts differ significantly (P <0.05).

Result

The effect of cannabis on copper induced hematological changes in wistar rats was presented in Table 1 below. There is decreased in PCV with statistically difference (P <0.05) between Group B compared to group A, C and D. There is no statistically difference in Hb (P>0.05) among the groups. Statistically difference (P<0.05) was observed with decreased RBC in group B compared to A, C and D. statistically also shows significant decreased

in WBC ($P < 0.05$) in group C compared to group B but there is no significant difference ($P > 0.05$) between A, C and D. MCHC and MCH also shows significant increase with statistical difference ($P < 0.05$) between group B compared to group A, C and D. There is statistically significant ($P < 0.05$) in group C when compared to group A, B and D. There is decreased in MCV with statistically significant ($P < 0.05$). Decrease in monocytes was also observed in group B compared to group A, C and D with statistically difference ($P < 0.05$). Lymphocytes, neutrophils, eosinophils and basophils show no significant changes in all groups.

Histopathology

Results of histopathological finding from Wistar rats showed no lesions on the heart in group all groups. The heart showed normal myocardium and endocardium with artifact (plate A-D).

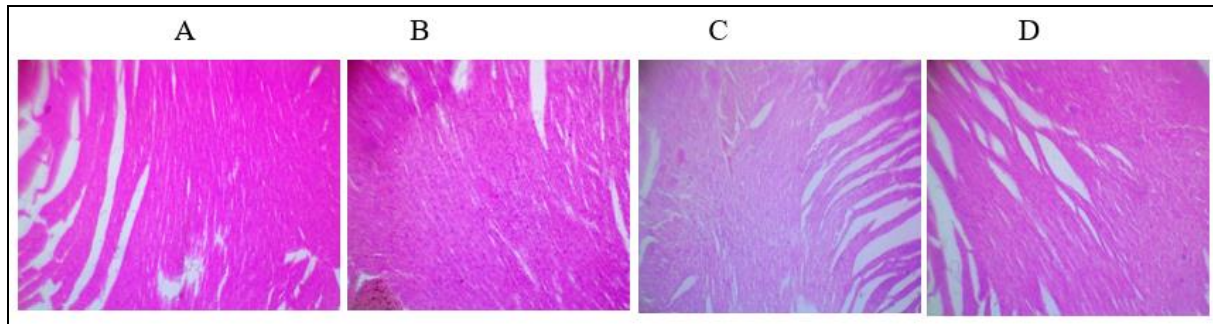


Plate 1-4: Histopathological assessment of the kidney of Wistar rats: The heart showed normal myocardium and endocardium with. Plate A; heart section of the Wistar rat fed with feed and water only (control group), Plate B; heart section of the Wistar rat exposed to CuO only, Plate C; heart section of the Wistar rat treated to G. egg methanol extract only Plate D; heart section of the Wistar rat treated to G. egg methanol extract and later exposed to CuO.

Discussion

Hematological parameters are essential in disease diagnosis, as they give information about the general condition of the body systems. It can also be used in monitoring or evaluating the efficacy of treatment (Do *vet al.*, 2020). Therefore, this study investigates those parameters and histological appearance of heart after exposure to copper (ii) oxide and cannabis extract.

This study showed decreased in PCV and RBC which is similar to the work of (Atamanalp & Yanik, 2003), who reported decreased values of erythrocytes, hemoglobin and hematocrit after exposure to heavy metal pollution. The decreased of PCV and RBC lead to anemia which occurred as a result of bone marrow suppression by the copper (Pieper, Friedmann, Jones, & Thornton, 2016). However, treatment with cannabis has not reversed the effect.

This study also showed decrease in WBC. The decrease may be as a result of copper effect on suppressing bone marrow activities by altering the maturation of lymphocytes, neutrophils, eosinophils, monocytes and basophils. These may be responsible for reduced immune and or defense mechanism as well as low blood count condition in most consumers (Weng *et al.*, 2017). The level of WBC was not reversed after treating with cannabis.

This study showed decreased in MCHC, MCH and MCV which is similar to the work of (Shah, 2006) who reported that, copper induced changes on hemato-biochemical parameters resulted to reduction in MCHC. The decreased of MCHC was due to ability of Copper to cause bone marrow suppression. However, after treating with cannabis the effect was not reversed (Weng *et al.*, 2017).

Histopathology shows no changes between the control and the treatment groups. This may be due to short time exposure of the rat to the CuO. Use of sub-lethal dose following toxicity study of the CuO to induce degenerative changes in heart also contributed to normal histological appearance.

This study showed decreased in monocytes, this is similar to the work of (Shah, 2006). who reported heavy metal pollution with copper causes decreased in monocytes? However, after treating with cannabis the effect was not reversed.

Conclusion and recommendations

The result of this study shows that copper caused changes in hematological parameters that lead to anemia. Treatment with cannabis caused relative increase in hematological parameters which was not significant enough to reverse the effect. However, the study showed cannabis causes polycythemia. Further researches should be conducted to investigate other means of treating copper toxicity.

References

1. Atamanalp M, Yanik T. Alterations in Hematological Parameters of Rainbow Trout (*Oncorhynchus mykiss*) Exposed to Mancozeb. *Turkish Journal of Veterinary and Animal Sciences*, 2003. <https://doi.org/10.46989/001c.20477>

2. Bergamaschi MM, Helena R, Queiroz C, Crippa JAS, Zuardi AW. Safety and Side Effects of Cannabidiol, a Cannabis sativa Constituent, 2011, 1.
3. Bewley-Taylor D, Jelsma M. Regime change: Re-visiting the 1961 Single Convention on Narcotic Drugs. *International Journal of Drug Policy*, 2012. <https://doi.org/10.1016/j.drugpo.2011.08.003>
4. Do Nascimento LMS, Bonfati LV, Freitas MLB, Mendes Junior JJA, Siqueira HV, Stevan SL. Sensors and systems for physical rehabilitation and health monitoring—a review, 2020. *Sensors (Switzerland)*. <https://doi.org/10.3390/s20154063>
5. Fasakin K. Modified Leishman Stain: The Mystery Unfolds. *British Journal of Medicine and Medical Research*, 2014. <https://doi.org/10.9734/bjmrr/2014/10855>
6. Fashola MO, Ngole-Jeme VM, Babalola OO. Heavy metal pollution from gold mines: Environmental effects and bacterial strategies for resistance. *International Journal of Environmental Research and Public Health*, 2016. <https://doi.org/10.3390/ijerph13111047>
7. Higgins C. Hemoglobin and its measurement, 2005.
8. Hunt N, Ashton M, Lenton S, Mitcheson L, Nelles B, Stimson G. A review of the evidence-base for harm reduction approaches to drug use. *Forward Thinking on Drugs*, 2003.
9. Kocis PT, Vrana KE. Delta-9-Tetrahydrocannabinol and Cannabidiol Drug-Drug Interactions. *Medical Cannabis and Cannabinoids*, 2020. <https://doi.org/10.1159/000507998>
10. Natt MP, Herrick CA. A New Blood Diluent for Counting the Erythrocytes and Leucocytes of the Chicken. *Poultry Science*, 2012. <https://doi.org/10.3382/ps.0310735>
11. Onyemaobi GA, Onimawo IA. Anaemia Prevalence among Under-five Children in Imo State, Nigeria. *Australian Journal of Basic and Applied Sciences*, 2011.
12. Park HR, Oh R, Wagner P, Panganiban R, Lu Q. New Insights Into Cellular Stress Responses to Environmental Metal Toxicants. In *International Review of Cell and Molecular Biology*, 2017. <https://doi.org/10.1016/bs.ircmb.2016.10.001>
13. Pieper IL, Friedmann Y, Jones A, Thornton C. Evaluation of Four Veterinary Hematology Analyzers for Bovine and Ovine Blood Counts for In Vitro Testing of Medical Devices. *Artificial Organs*, 2016. <https://doi.org/10.1111/aor.12703>
14. Rehman M, Liu L, Wang Q, Saleem MH, Bashir S, Ullah S, Peng D. Copper environmental toxicology, recent advances, and future outlook: a review. *Environmental Science and Pollution Research*, 2019. <https://doi.org/10.1007/s11356-019-05073-6>
15. Sabyusheva Litschauer I, Becker K, Saghafi S, Ballke S, Bollwein C, Foroughipour M et al. 3D histopathology of human tumours by fast clearing and ultramicroscopy, 2020. *Scientific Reports*. <https://doi.org/10.1038/s41598-020-71737-w>
16. Shah SL. Hematological parameters in tench *Tinca tinca* after short term exposure to lead. *Journal of Applied Toxicology*, 2006. <https://doi.org/10.1002/jat.1129>
17. Weng L, Boda SK, Teusink MJ, Shuler FD, Li X, Xie J. Binary Doping of Strontium and Copper Enhancing Osteogenesis and Angiogenesis of Bioactive Glass Nanofibers while Suppressing Osteoclast Activity. *ACS Applied Materials and Interfaces*, 2017. <https://doi.org/10.1021/acsami.7b06521>
18. Yalcinkaya T, Uzilday B, Ozgur R, Turkan I, Mano J. Lipid peroxidation-derived reactive carbonyl species (RCS): Their interaction with ROS and cellular redox during environmental stresses, 2019. *Environmental and Experimental Botany*. <https://doi.org/10.1016/j.envexpbot.2019.06.004>